

## The peripheral nerve ends in the tongue of the harbour porpoise *Phocoena phocoena* (Linne, 1758)

Günther Behrmann

Alfred-Wegener-Institut für Polar- und Meeresforschung, 2850 Bremerhaven, West Germany

### Introduction

Tongues (Lingua) of dead harbour porpoises are much smaller than those of comparable terrestrial mammals (Boenninghaus, 1903). With the exception of a small area at the tip of the tongue, the entire margin (Margo linguae) is covered with papillae (Papillae fungiformis). A longitudinal section through the tongue shows differences when compared with the tongues of terrestrial mammals, their inner parts consist of muscles. The inner parts of harbour porpoise tongue and of their papillae consist of cavernous tissue (Corpus cavernosus) and muscles are very poorly developed. The corpus cavernosus is an extension of the venous vessel system and enable it to carry larger quantities of blood (Boenninghaus, 1903). The corpus cavernosus is covered by the integument (Integumentum commune). The boundary lines between different skin parts, the subcuticle (Tela subcutanae), corium (Corium) and the cuticle (Epidermis), are clearly recognized. The cuticle is covered with a squamous muscosa. This means that the integument of the tongue of the harbour porpoise is of the same structure as the integument of other terrestrial mammals. Some toothed whales possess taste buds, but mainly of a residual nature (Stadtmüller, 1938). The anatomy of odontocete brains shows that they are able to taste. It is also confirmed that toothed whales can use the tip and the margin of their tongues as organs of touch (Caldwell & Caldwell, 1972).

If the harbour porpoise is able to taste and to touch, its tongue must have nervous receptors. As the integument of the harbour porpoise tongue is similar to the one of other mammals, it was important to find out whether its nerves are comparable to the nerves of the tongues of terrestrial mammals, and how sensitive they are.

### Material and Methods

Two harbour porpoise tongues were sectioned to prepare macroscopical and histological sections. A special histological colouring with lithium carbo-

nate, combined with different colour filters permitted the determination of nerves and the nervous end-corporuscles.

The photographs of the histological sections were taken with phasecontrast objectives. Magnifications indicated in the text refer only to optical and not to photographic magnifications.

### Results

In the integument of the tongue (Figure 12) and of the papillae (Figure 11) are many nerves and nervous end-corporuscles. However, the numbers of the nerve ends decrease caudally, and millimeters behind the tips and the bases of the papillae, nerves became very poor. It is remarkable that in the skin of the tips of the tongue (Apex linguae) and of the papillae, there exist numerous concentrations of nerve-ends (Figure 18).

The uncovered free ends of the nerves ramify out of covered nerve fibres (Axon) (Figure 13, Figure 14A). Many thick fascicles of nerves covered with perineurium are present in the cuticles and in the subcuticle. These nerves fascicles combine sensitive, motor and vegetative nerve fibres (Leonhardt, 1985) (Figure 13 NB). In the epidermis different shapes of

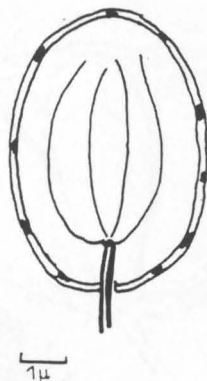
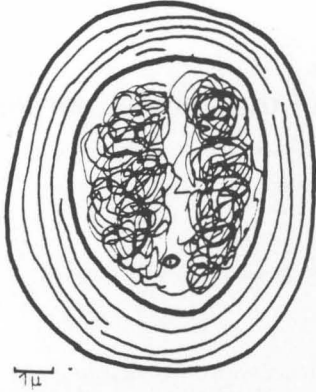
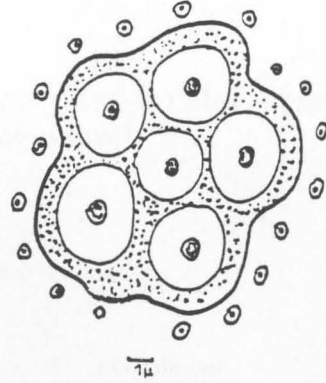


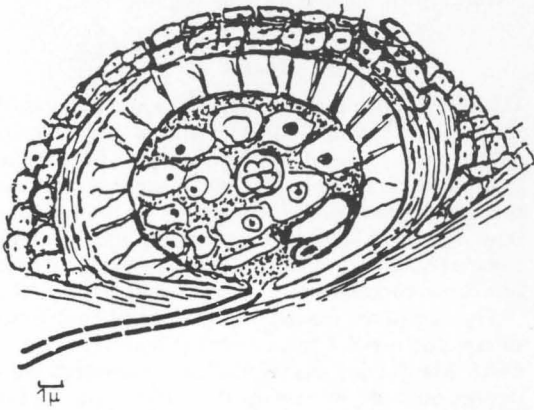
Figure 1. Longitudinal section through an oval nerve end-corporuscle. Inside, the nervous dendrites ramify like a chandelier (Figure 15 OE).



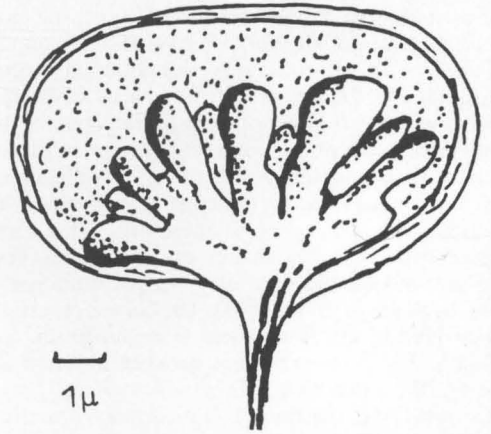
**Figure 2.** Golgi-Mazoni corpuscle covered by a voluminous stratum of connective tissue. Inside, the nerves ramify irregularly (Figure 16 GM).



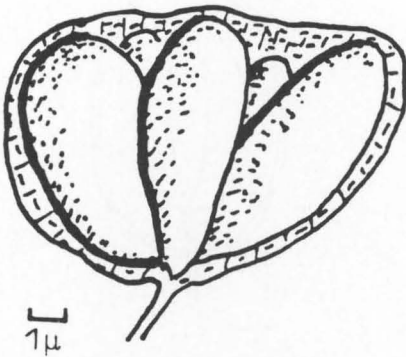
**Figure 5.** Transverse section through the tuberos organ (Figure 4).



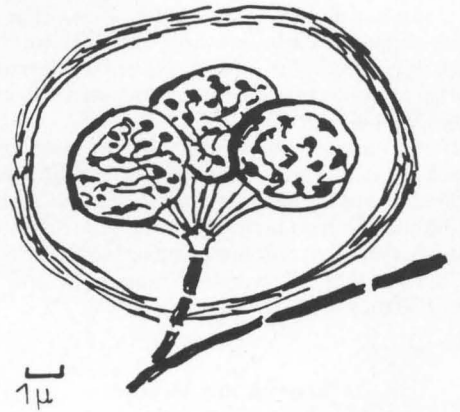
**Figure 3.** Meißner tactile corpuscle in a cyst by collagenous fibrils (Figure 17 KF).



**Figure 6.** Multi-tuberos organ situated near the epidermis. The swellings are differently formed (Figure 13 VTU).



**Figure 4.** Tuberos organ with six swellings situated in the subcutica (Figure 5, Figure 13 TU).



**Figure 7.** Cyst with ampoulate nervous end-corpuscles (Figure 18 BE). In many cysts the corpuscles are shrunk (Figure 8).

nervous end-corporcules are found (Figures 1-8). There exist three kinds of mechano-receptors (Hirsch *et al.*, 1973; Welsch & Storch, 1973; Leonhardt, 1985) all over the skin of the tongue (Figures 1-3). Another three kinds of nervous end-corporcules were detected only in the tip of the tongue (Figures 4-8).

The following nervous end-corporcules exist in the tongue of harbour porpoise:

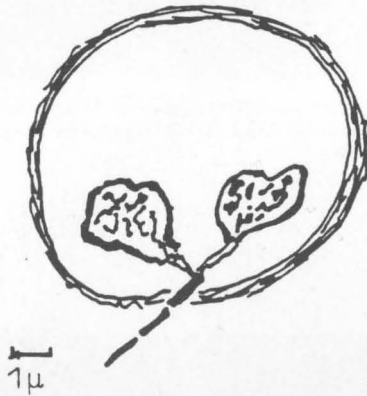


Figure 8. Shrunken ampoules.

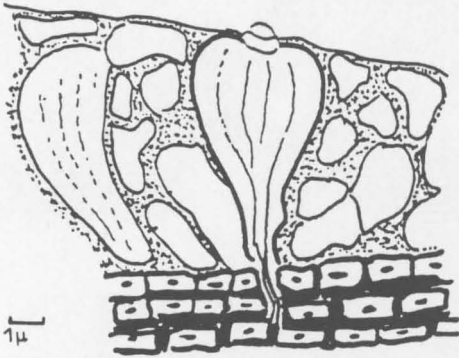


Figure 9. Taste buds situated in the mucosa of the stems of papillae (Figure 19 GS).

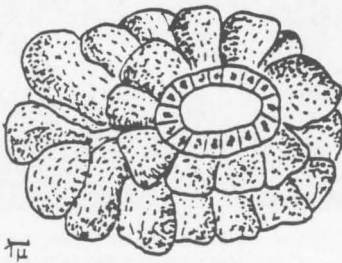


Figure 10. A muscus alveola gland, situated in the subcutica of the papillae.

## Discussion

Observation by the author at whale stations showed that tongues of living harbour porpoises are larger than of dead ones. This leads back to the corpus cavernosus. If the blood-pressure is reduced or the animal dies, the corpus cavernosus is compressed by muscles and empties and the tongue gets smaller.

The anatomy of the brain in toothed whales indicates that they are able to taste (Caldwell & Caldwell, 1972). This is demonstrated by the large number of functional taste buds on the stems of the papillae. Because the mucosa of dead animals is

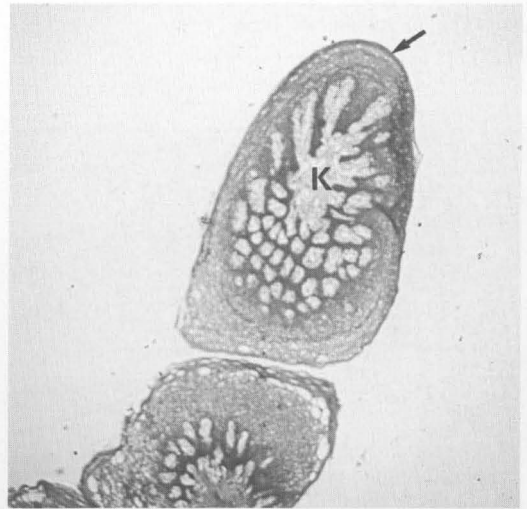


Figure 11. Longitudinal section through a papilla, magnification  $10\times$ . In the centre the cavernous corpus (K). The dark peripheral integument presents concentrations of nerve-ends.

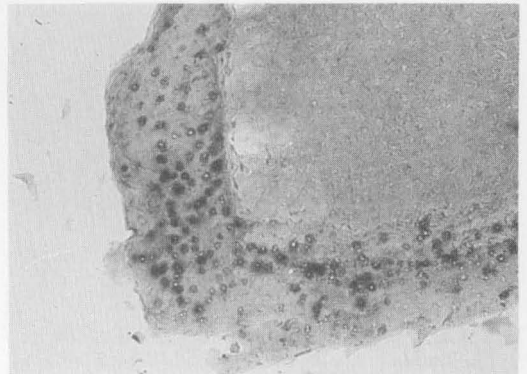
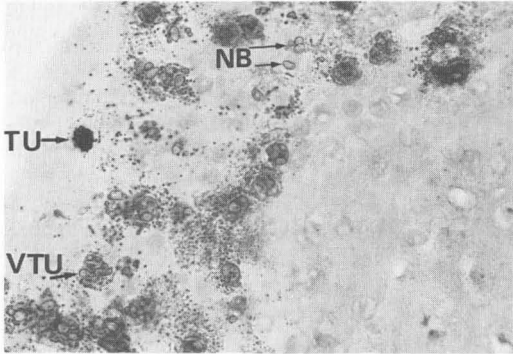
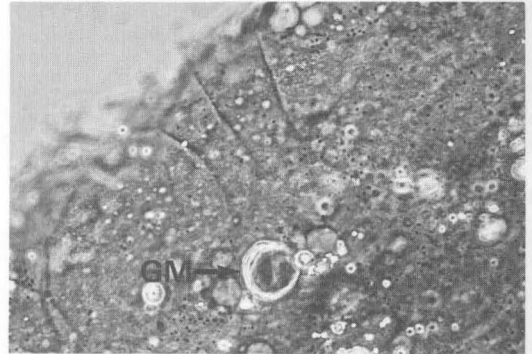


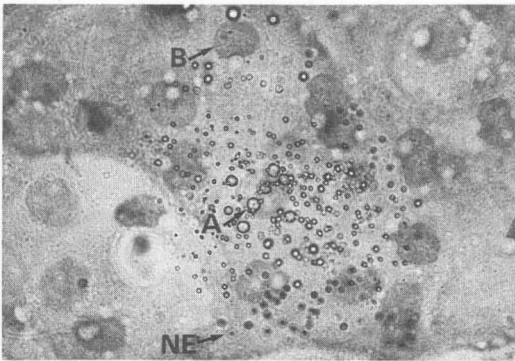
Figure 12. Longitudinal section through the tip of the tongue, magnification  $25\times$ . Every dark point is an accumulation of a large number of peripheral nerve-ends.



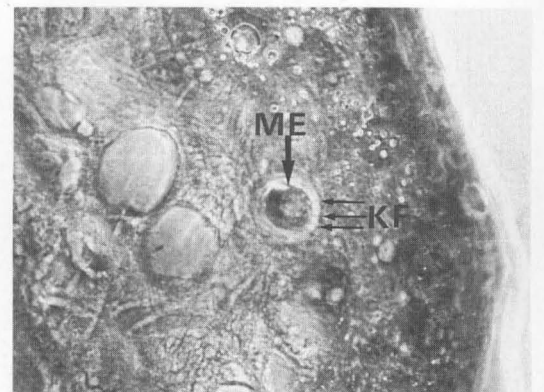
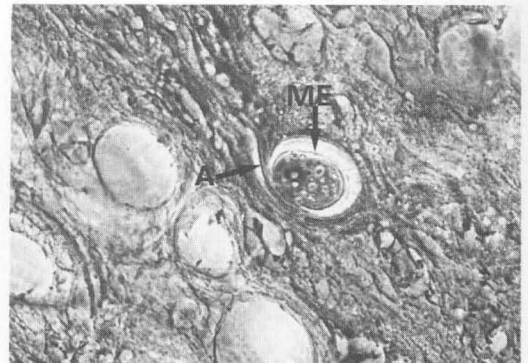**Figure 13.** Transverse section through the tip of the tongue, magnification 100 ×. Nerve fascicles (NB), tuberosus organ (TU), multi-tuberosus organ (VTU).



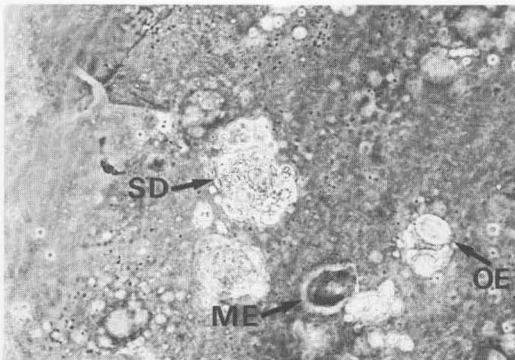
**Figure 16.** Transverse section of a Golgi-Mazoni corpuscle (GM), magnification 250 ×. The lamellas of the conjunctiva are clearly seen.



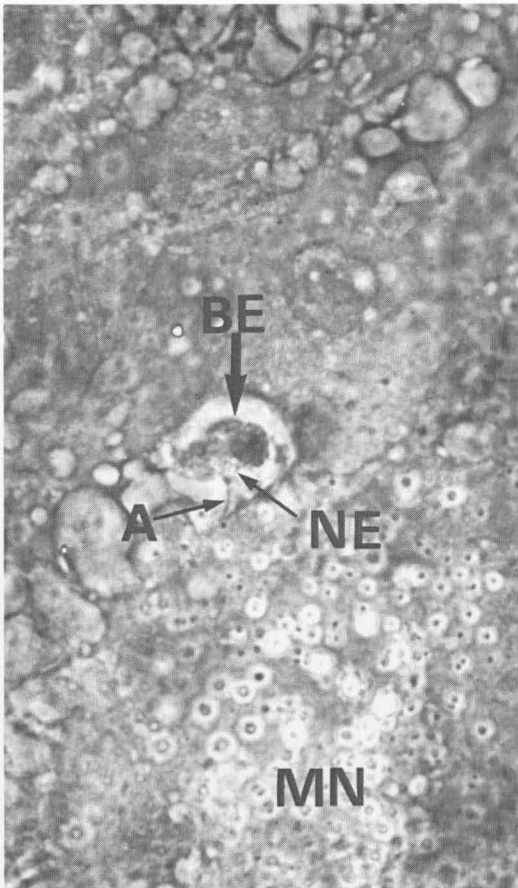
**Figure 14.** Clusters of peripheral nerves in the tip of the tongue, magnification 250 ×. Covered peripheral nerve (A), uncovered nerve (NE), blood corpuscle (B) Ø 8µ for comparison.



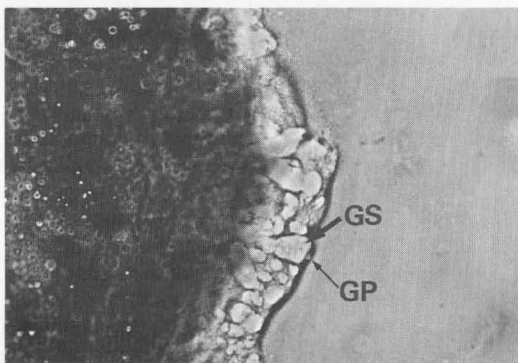
**Figure 17.** Meißner tactile corpuscle (ME), magnification 250 ×. Upper part: a transverse section with the incoming nerve (A). Lower part: A horizontal section of the Meißner tactile corpuscle with collagenous fibrils.



**Figure 15.** Horizontal section through the integument, magnification 250 ×. Serous mucus gland (SD), oval corpuscle (OE), Meißner-tactile corpuscle (ME).



**Figure 18.** Cyst with three ampoulate nervous end-corpuscle (BE), magnification 250 ×. From the axon (A) neurites (NE) ramify to the nervous end-corpuscles. Below: an uncovered neurite (NE).



**Figure 19.** Mucosa of the stem of the papilla, magnification 250 ×. Longitudinal section through a taste bud (GS) and a taste pore (GP).

quickly eroded, in former times it was believed that the sense organs for taste exist only rudimentarily (Stadtmüller, 1938). It is therefore possible that in well preserved tongues of toothed whales taste buds could be discovered in other parts of the tongue.

'Conversely, behavioural observations lead to the conclusion that the sense of touch is one of the most important sense in dolphins' (Caldwell & Caldwell, 1972). Because the skin of whales is very thick, it is supposed that touch-regions may be situated in areas where the skin is very thin, e.g. at the tip of the rostrum or the tongue. The great number of free nerve-ends and the accumulation of nervous end-corpuses confirms this.

Through the many free nerve-ends toothed whales can register pain, heat and cold (Leonhardt, 1985); with the mechanoreceptors situated in the whole skin of the tongue, they can register touch (Welsch & Storch, 1973; Hirsch *et al.*, 1973; Leonhardt, 1985). The function of the nerve-corpuses in the tip of the tongue (Figure 4-8) are unknown. Comparable corpuses are described in connection with lateral electroreceptive organs of mormyrid fishes (Boek, 1934; Szabo & Yvette, 1974). Further studies are required.

Much of the small ampulate nervous end-corpuses (Figure 7) are shrunk (Figure 8). This may result from stress before death. In situations of stress, adrenaline pours out and the nervous receptors are paralysed for some time (Albert *et al.*, 1986).

The tongue of the harbour porpoise is a highly sensitive organ and may even be more sensitive than the tongues of terrestrial mammals. This may be the reason why harbour porpoises avoid estuaries and coastal waters, which in past times were their preferred milieu.

#### Key

A	Axon
B	Blood-corpucle
BE	Ampoulate organ
EK	Nervous end-corpucle
GP	Taste organ
K	Corpus cavernosus
KF	Collagenous fibres
ME	Meißner-touch-corpucle
MN	Myelinated neuron
NB	Nerve bundles
NE	Neuron
NS	Nerve fibre
OE	Oval corpucle
SD	Mucous gland
SH	Mucosa
S	Schwann cell
SS	Myelin sheath
TU	Tuberous organ
VTU	Multi-tuberous organ

## References

- Alberts, B., Bray, D., Lewis, J., Raff, M., Roberts, K. & Watson, J. D. (1986). *Molekularbiologie der Zelle*. VCH Verlagsgesellschaft mbH, Weinheim 1310 pp.
- Boeke, J. (1934). *Niedere Sinnesorgane*. Handbuch der vergleichenden Anatomie der Wirbeltiere, B. 2/2. Verlag Urban und Schwarzenberg, Berlin und Wien. pp 855–878.
- Boenninghaus, G. (1903). *Der Rachen von Phocoena communis* Less. *Zoologische Jahrbücher. Abteilung Anatomie und Ontogenie der Tiere*. Verlag, G. Fischer, Jena. pp. 1–92.
- Caldwell, D. K. & Caldwell, M. C. (1972). Senses and communication. In: Sam H. Ridgway (Ed.) *Mammals of the Sea*. Charles C. Thomas, Springfield, Illinois, USA. pp. 466–496.
- Hirsch, G. C., Ruska, H. & Sitte, P. S. (1973). *Grundlagen der Cytologie*. Gustav Fischer Verlag, Stuttgart. 790 pp.
- Leonhardt, H. (1985). *Histologie, Zytologie und Mikro-anatomie des Menschen*. Thieme Verlag, Stuttgart, New York. Band 3: 1–498.
- Simpson, J. G. (1972). Comparative microscopic anatomy of selected marine mammals. In: Sam H. Ridgway (Ed.) *Mammals of the Sea*. Charles C. Thomas, Springfield, Illinois, USA. pp. 298–413.
- Sonntag, G. F. (1922). The comparative anatomy of the tongues of the mammalia. *Proceedings of the Zoological Society of London*, Vol. VII, 639–657.
- Stadtmüller, F. (1938). *Mundöffnung, Lippen, Wangen, Vestibulum oris*, Handbuch der vergleichenden Anatomie der Wirbeltiere. Verlag Urban und Schwarzenberg, Berlin und Wien. Band 5: 895–1010.
- Szabo, T. & Gif sur Yvette, (1974). Anatomy of the specialized lateral line organs of electroreception. *Handbook of sensory physiology* (ed. Fassard). Springer-Verlag, Berlin, Heidelberg, New York. B. III/3: 14–58.
- Welsch, U. & Storch, V. (1973). *Einführung in die Cytologie und Histologie der Tiere*. Gustav Fischer, Verlag, Stuttgart. 569 pp.