

Symposium
« Whales: Biology – Threats – Conservation »
(Brussels, 5-7 June 1991)
Proceedings edited by J.J. Symoens
Royal Academy
of Overseas Sciences (Brussels)
pp. 149-156 (1992)

THE PERIPHERAL NERVE ENDINGS
IN THE SKIN OF THE HARBOUR PORPOISE
PHOCOENA PHOCOENA (LINNÉ 1758)

BY

G. BEHRMANN *

SUMMARY. — Harbour porpoises live in estuaries and coastal waters, which have a natural pollution. During their evolution, harbour porpoises have adapted to life in muddy water with reduced visibility. Their echolocation system is therefore highly developed, as well as their senses of taste, smell and touch. The nerve-endings of the touch sense are primarily situated in the skin, which is rubber-like, soft and smooth. It is interesting to know how sensitive the skin is. The integument possesses an epidermal layer up to 4 mm thick. The superficial layer with parakeratotic cells is up to ten layers deep, and can be up to 40 µm thick. The other epidermal layer has polyhedral prickle cells and extends peg-like into the cuticular layer. Melanocytes are accumulated in the stratum spinosum and in the thin basal layer. The whole integument is penetrated by myelinated and free merckless nerve-endings, and many kinds of nervous corpuscles, as known from amphibians, fish, birds, mammals. These as well as new forms of nerve-endings are demonstrated and their possible function is discussed in relation to their morphology and location.

* * *

The epidermal layer is nearly 4 mm thick and penetrated by myelinated and merckless free ending nerves, and many types of nervous end corpuscles, as known from amphibians, fish, birds, and mammals (MALINOVSKY 1986 & QUILLIAM *et al.* 1966). These, as well as up to 21 new forms, could be identified, but I assume that there exist even more.

In the dark area melanocytes (Plate 1, Fig. 1) are accumulated. They do not belong to the nervous system, but to prevent mistakes in determination, they are added. Cells of Langerhans (Plate 1, Fig. 2)

* Nordseemuseum, Am Handelshafen 12, D-2850 Bremerhaven (Germany).

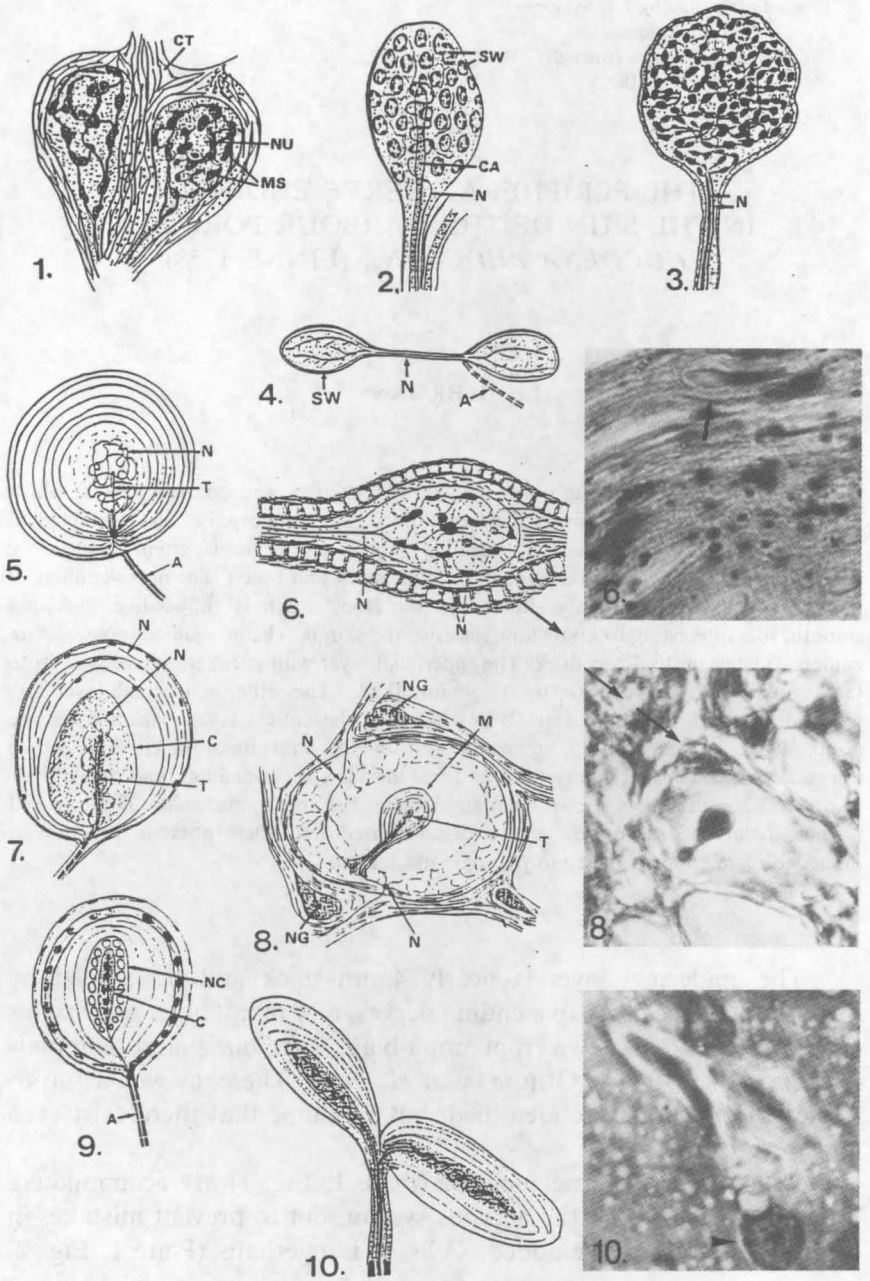


Plate 1

carry pigment-granules and are penetrated by neurites; they are therefore interpreted as neuro-vegetative cells. They have a length of up to 3 μm , are situated in the cuticle layer, and have a function within the immune system.

Primitive end corpuscles of Krause (1858) (Plate 1, Fig. 3) were found in many variations in all layers of the integument, frequently near, or in connection with other end corpuscles (10.◀, 18.◀, 21.NE). They have a diameter of up to 10 μm , and could be supply corpuscles. Nervous tandem corpuscles (Plate 1, Fig. 4) are known from the membrane of the sound bladder of frogs, two small swellings with a length of up to 3 μm , combined by a capillary and merkleless nerves.

Numerous tandem end corpuscles are situated in the cornea of the tongue and in the upper epidermal layer of the nosehole. They perceive stretchings of the skin. Of the lamellated touch corpuscles seven types are clearly discernible (Plate 1, Figs. 5-10), Plate 2, Figs. 11 and 12). All lamellated touch corpuscles have a terminal nerve in the centre, surrounded by a core, which is covered by lamellae of connective tissue. They are all able to perceive the intensity of pressures. Up to ten lamellae have the variant of the Golgi-Mazzonian touch corpuscle. The roundish type 5 has a diameter of nearly 12 μm , and is situated in the whole skin. The oval type 7 can have a length of up to 30 μm , and is only found in the upper epidermal layers of the tongue and its papillae. A new variant of such touch corpuscles (Plate 1, Fig. 8) was discovered in the vessels of the swell corpus of the tongue papillae. With a length of only 6 μm it is the smallest known. In the connective tissue, covering the vesicles of the swell corpus, neuroglia cells (Plate 1, Fig. 6) are situated. They regulate the development of tissue. Lamellated touch corpuscles of Herbst (Plate 1, Fig. 9) were found in the upper epidermal layer of the tongue and have a diameter of up to 15 μm . Their longish core is surrounded by nerve cells. They are comparable to the touch corpuscles, which are situated in the bill of ducks (QUILLIAM 1966). With an extension of about 150 μm , the lamellated touch corpuscles of Ruffini (Plate 1, Fig. 10) are the greatest of this type. Two longish spray-like lamellated end corpuscles are in their structure comparable to the Golgi-Mazzonian touch corpuscles. They are situated in the epidermal layer of the tongue ground and in cutical layers of the accessory sacs of the nosehole. They are described as stretch corpuscles of birds and mammals (MALINOVSKY 1986). In deeper layers of

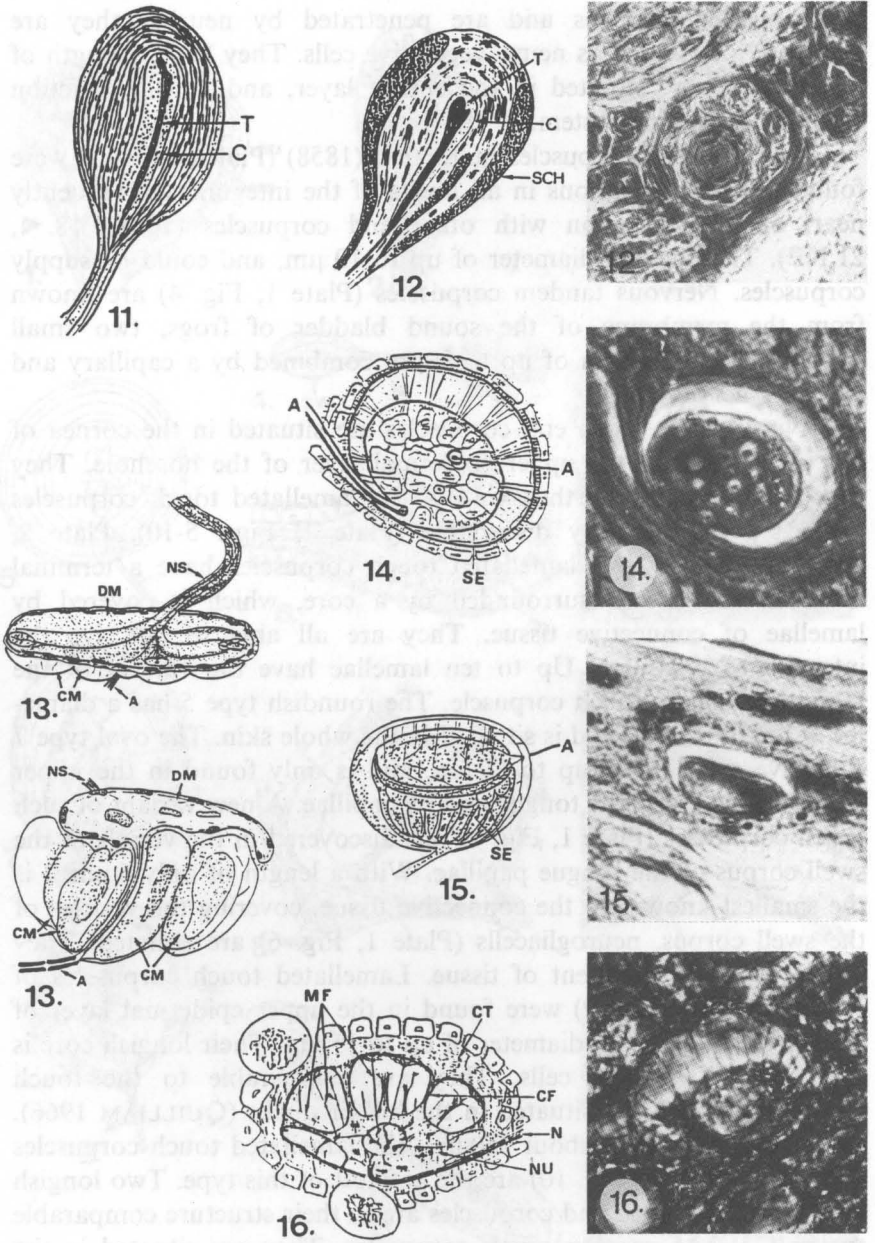
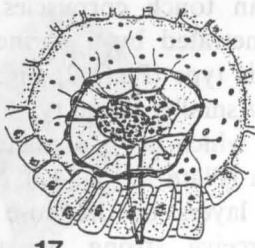


Plate 2

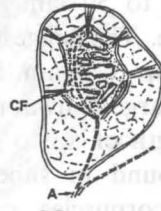
the cutis, near the muscles, Vater-Pacinian touch corpuscles are situated. They have 30 to 50 lamellae penetrated by a perineural network, and a big core. The biggest of this type (Plate 2, Fig. 11) could have a length of up to 5 mm. Slightly smaller is the type with nearly 20 lamellae and large Schwann cells, which has a diameter of nearly 60 μm and a length of up to 300 μm (Plate 2, Fig. 12). Such end corpuscles were found in subcuticle layers of the nose tip. Vater-Pacinian touch corpuscles can perceive strong pressures. Meissner corpuscles (Plate 2, Fig. 14) are situated in cutical layers of the whole skin and have a diameter of up to 100 μm . Out of a floating end corpuscle, composed of sensory cells, collagen fibrils extend to the tissue surrounding the capsule. The movement of the skin is mechanically transmitted to the sensory cells. A new type, perhaps a variant of the Meissner corpuscles, is situated in the parakeraotic and the epidermal layers, nearly 20 μm below the surface of the skin. The capsules have a length of up to 30 μm . The half roundish end corpuscle has a disk orientated in parallel to the surface. Out of the disk extend nerve fibres to the tissue of the capsule. The fibres transmit rapid tender surface load to the disk. Such end corpuscles may perceive turbulences which developed in time of fast swimming. A higher developed end corpuscle situated nearly 150 μm below the skin surface, especially in the skin of the forehead, is type 16. Out of the corpuscle, fixed by collagenous fibres to the tissue of the capsule, extend moss fibres, ramifying in the wall of the capsule. It has a length of up to 60 μm . In case of the moss fibres, such corpuscles are able to perceive tender vibrations and loads of the skin. Meissner touch corpuscles (Plate 3, Fig. 18) in the photograph accompanied by a corpuscle of Krause (\blacktriangleleft), have a diameter of up to 25 μm and are situated in all layers of the skin.

Grandry corpuscles (Plate 3, Fig. 17) are situated in the same area. The capsules have a diameter of up to 10 μm . Out of two or three primitive nervous end corpuscles extend nerve fibres penetrating the tissue of the capsule and endings in the cells around the capsule. «Grandry corpuscles are typical subepidermal endings in the beak of aquatic birds, are afferent units with rapid adaptation» (MALINOWSKY 1986).

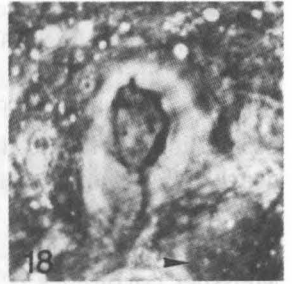In the epidermis of the tip of the tongue and the papillae two types of ampulla-like nervous end organs were found. In a capsule with a diameter of nearly 12 μm , three oval sensory cells with a diameter of nearly 3 μm float (Plate 3, Fig. 20). An axon leads into the capsule,



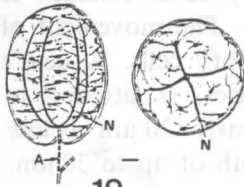
17.



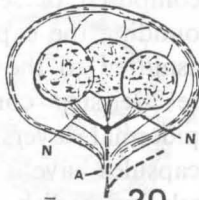
18.



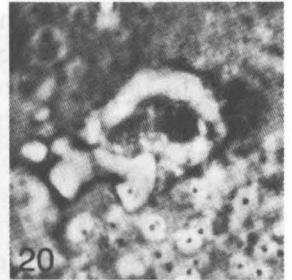
18



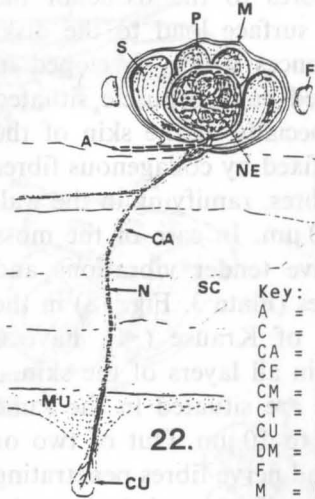
19.



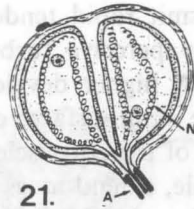
20.



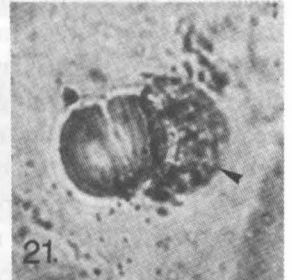
20



22.



21.



21

Key:

- A = Axon
- C = Core
- CA = Capillary
- CF = Collagenous fibres
- CM = Cell of Merkel
- CT = Connective tissue
- CU = Cupula
- DM = Disk of Merkel
- F = Foodcell
- M = Membrane
- MF = Moss fibres/Nerves
- MS = Melanosome
- MU = Mucosa

- N = Nerve/Neurit
- NC = Nerve cell
- NE = Nerve end-corpuscle
- NG = Neuroglia cell
- NS = Nerve strung
- NU = Nucleus
- P = Pore
- S = Secretory cell
- SC = Stratum corneum
- SE = Sense cell
- SW = Swelling
- SCH = Schwann cell
- T = Terminal nerve

and its nerve fibres lead to the ampoules (BEHRMANN 1988). Comparable organs are described in connection with electroreceptive organs of mormyrid fish (SZABO 1974). In the same area, oval ampulla-like organs (Plate 3, Fig. 19) with a diameter of a little more than 15 μm were situated (BEHRMANN 1988). The oval ampullae have a length of up to 10 μm and a diameter of up to 5 μm . The neurite leading into the capsule is ramified like a chandelier. The function of these organs is unknown. Well-known are the ampulla-like end corpuscles of Grandry. Comparable organs were found in the bill of ducks and in the tongue of woodpeckers (QUILLIAM 1966). Such corpuscles (Plate 3, Fig. 21) are situated in the tip of the lower lip and in the tip of the tongue. Two half-roundish ampoules form together an organ with a diameter of nearly 10 μm . The ampoules are penetrated by spring-shaped nerve terminals and primitive nerve fibres.

Two highly developed nervous organs were identified. Tactile disks of Merkel (Plate 2, Fig. 13, above the surface, below a cross section) consist of 4 to 7 tall Merkel cells and a longish disk, with a length of nearly 30 μm . They are situated in the parakeraotic layers of the upper and lower jaw, in the nose tip and in the opening of the blowhole. Such organs are described as specialized touch corpuscles. A new type of nervous organ was detected in the epidermis of the tongue tip. The organ is a combination of 5 to 8 nervous secretory cells and a nervous end corpuscle in the centre (Plate 3, Fig. 22). Out of the organ with a diameter of nearly 30 μm , leads a capillary with a length of nearly 50 μm to the surface. In the capillary, a nerve, extending out of the end corpuscle, draws to the surface, and ends in a gelatinous cupula. This organ could be a receptor of electric or magnetic waves (BEHRMANN 1990).

With the broad spectrum of nerve endings, the harbour porpoise, and perhaps other whales, have the best developed peripheral nerve system of all animals.

REFERENCES

- BEHRMANN, G. 1988. The peripheral nerve ends in the tongue of the harbour porpoise. — *Aquatic Mammals*, **14**(3): 107-112.
- BEHRMANN, G. 1990. The tuberous organs of the harbour porpoise *Phocoena phocoena* (Linné 1758). — *Aquatic Mammals*, **16**(1): 33-35.

- MALINOVSKY, L. 1986. Mechanoreceptors and free nerve endings. — *In*: BER-EITER-HAHN, J., MATOLTSY, A. G. & RICHARDS, K. S. (eds.), *Biology of the integument 2*. — Springer-Verlag, Berlin, Heidelberg, New York, pp. 535-603.
- QUILLIAM, T. A. 1966. Structure of the reception organs. — *In*: DE REUCK, A. V. S. & KNIGHT, J. (eds.). *Touch heat and pain*. J. & A. Churchill, London, pp. 86-116.
- SZABO, T. 1974. Anatomy of specialized lateral line organs of electroreception. — *In*: FASSARD (ed.), *Handbook of Sensory Physiology*, 3. — Springer-Verlag, Berlin, Heidelberg, New York, pp. 14-18.

REFERENCES

- BEHRMANN, G. 1988. The peripheral nerve ends in the trunk of the harbor porpoise. — *Anatomie Monograph*, 14(3): 107-112.
- BEHRMANN, G. 1990. The tubercous organs of the harbor porpoise *Phocoena phocoena* (Linne 1758). — *Anatomie Monograph*, 16(1): 33-37.